

Ultrasonic aspiration in neuroendoscopy: first results with a new tool

Technical note

JOACHIM OERTEL, M.D., PH.D.,¹ JOACHIM KURT KRAUSS, M.D., PH.D.,²
AND MICHAEL ROBERT GAAB, M.D., PH.D.¹

¹Department of Neurosurgery, Hannover Nordstadt Hospital; and ²Department of Neurosurgery, Hannover Medical School, Germany

Neuroendoscopic techniques are often considered inapplicable to lesion resection because most lesions are too large for effective endoscopic resection in an appropriate time frame. To evaluate the potential of ultrasonic aspiration in neuroendoscopic procedures, the authors developed a new handpiece for endoscopic application. The instrument was subsequently tested in 10 cadaveric pig brains and applied in 5 clinical cases. In the pig brain, a precise and accurate aspiration of ventricular ependyma and brain parenchyma was obtained. Clinically, the device was applied in 3 patients with obstructive hydrocephalus, and via an endonasal transsphenoidal approach in 2 patients with pituitary macroadenomas. In all cases, the lesion was effectively aspirated without complications. Ultrasonic aspiration can be applied safely and successfully in selected endoscopic procedures. The use of this technique could expand the indications for endoscopic approaches to include intraventricular lesions and in minimally invasive transsphenoidal endonasal approaches. (DOI: 10.3171/JNS/2008/109/11/0908)

Key Words • intraventricular lesion • neuroendoscopy • pig • pituitary adenoma • ultrasonic aspirator

INTRACRANIAL endoscopy is a valuable technique for various indications in neurosurgery. However, its application in intraventricular lesions is often limited to biopsy and cerebrospinal fluid pathway restoration because lesion removal is considered to be rather time consuming.⁸ Ultrasonic aspiration, on the other hand, represents a well-established technique for fast and effective tissue removal in certain neurosurgical applications.^{3,10,12,13,16} Therefore, the goal of the present study was to develop and investigate an ultrasonic aspirator tip for endoscopic applications.

Methods

Study Design

We tested a specially developed ultrasonic aspirator handpiece “under water” in 10 porcine cadaver brains. The handpiece was subsequently evaluated in 5 clinical endoscopic applications. Experimentally, the ultrasonic aspirator was tested for aspiration precision and efficacy under water. Clinically, the instrument was first applied in 2 cases of pituitary macroadenoma that were approached via an endonasal transsphenoidal route to gain a first impression of the ultrasonic aspirator under clinical conditions. After this initial testing, aspirator performance was

examined in 2 patients with third ventricular hemorrhages causing obstructive hydrocephalus and in 1 patient at the cyst membrane in a craniopharyngioma.

Technical Description of the Ultrasonic Aspirator System

For all procedures, a Sonoca 300 ultrasonic aspirator system was used (Söring GmbH). The frequency range is 20–80 kHz, and the vacuum suction is 0–0.9 bar. We developed a handpiece that fits perfectly in the GAAB working optical device (Fig. 1).

The universal GAAB neuroendoscopic system (Karl Storz GmbH & Co.) developed by the senior author was applied.⁸ All procedures were performed with rigid 0° rod-lens Hopkins optics and the standard operating sheath. A xenon light source, a digital camera, a video monitor, an automated irrigation pump, and the AIDA system for digital recording completed the endoscopic equipment (Karl Storz GmbH & Co). The neuroendoscopic system has been approved for neurosurgical use in countries throughout the world, including Germany and the US.

Experimental Application

The new handpiece was first tested under water with 20, 40, 60, 80, and 100% amplitude to investigate the aspiration effect of the handpiece at the wall of the lateral

Ultrasonic aspiration in neuroendoscopy




FIG. 1. Photographs of the ultrasonic aspirator handpiece with working optics, working channel, and endoscopy camera (left), and the handpiece in the endoscopic work sheath (right).

ventricle of 10 fresh, unfixed cadaveric porcine brains at 37°C. The accuracy and reliability of tissue aspiration, problems with visibility, and the application of the suction were noted immediately after each operation. All procedures were recorded on video. Histological evaluation followed, including measurement of the cutting depth.

Clinical Application and Surgical Procedure

The device was first applied clinically in 2 pituitary macroadenomas that were approached via an endonasal transsphenoidal route. The pituitary adenoma cases were selected because the sella anatomy does not vary widely and the procedure is very standardized. Also, in case of any complications, a switch to the microscope can be made without any difficulty and hesitation. The ultrasonic aspirator was next applied in 2 patients with obstructive hydrocephalus caused by intraventricular hemorrhage and blockage of the aqueduct, and in 1 patient with obstructive hydrocephalus caused by blockage of the aqueduct by a cystic craniopharyngioma. Consent was obtained from all patients for the use of the ultrasonic aspirator in conjunction with the endoscopic technique. All clinical procedures were performed in general anesthesia with the patient in supine position and the head fixed in a 3-pin head holder. The efficacy of tissue aspiration was evaluated and additionally analyzed semiquantitatively according to the following scale: Grade 1, no or very little aspiration effect; Grade 2, good effect with reliable tissue aspiration and moderate velocity; and Grade 3, excellent effect with fast and reliable tissue aspiration.

Results

Experimental Application

Reliable, accurate, and effective aspiration of the paraventricular brain parenchyma was obtained in the porcine brain under water. With great suction force, vigorous water movements were observed. Thus, all further procedures were performed under minimal suction, strong enough to suck tissue debris away but low enough to avoid blurring of vision. A rather loose correlation between applied aspiration force and aspiration depth was found (Fig. 2). Particularly at low amplitudes, the brain parenchyma was often not completely destroyed and aspirated tissue pieces remained adherent to the brain parenchyma. At higher amplitudes, a very effective and accurate tissue aspiration could be achieved (Figs. 3 and 4). Also, at higher amplitudes the standard deviation of the achieved tissue aspiration depth was rather small compared with results obtained at lower amplitudes (Fig. 2).

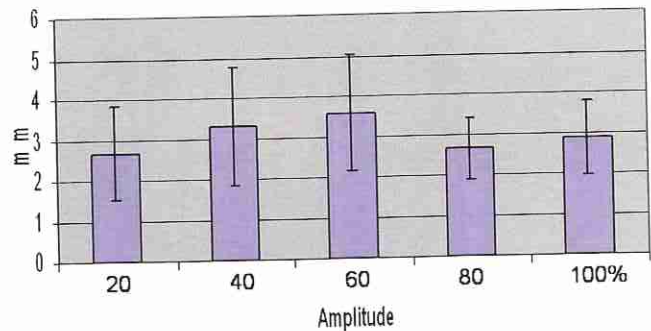


FIG. 2. Graph showing the mean aspiration depth under water with standard deviation at the lateral ventricle parenchyma in the porcine cadaveric brain.

Clinical Application

All procedures were performed with the patient supine and after induction of general anesthesia, with the head fixed in a 3-pin headholder device. In endonasal transsphenoidal pituitary adenoma surgery, a standard approach to the sella was made through a nostril with use of a nasal speculum. For a detailed description of the technique refer to Oertel and Gaab.¹¹

In intraventricular endoscopy, a standard approach to the lateral ventricle with the endoscopic sheath was performed, the trocar was removed and the 0° working optic lens was inserted. In the patient with the craniopharyngioma, the cyst wall was coagulated and aspirated with the ultrasonic aspirator. In the patients with intraventricular hemorrhage-related hydrocephalus, the operating sheath was carefully advanced through the foramen of Monro under direct view, and the hematoma blocking the approach to the floor of the third ventricle was aspirated using the handpiece. Afterwards, the ideal point for perforation of the floor of the third ventricle was identified at the midline between the mammillary bodies and the infundibular recess, and a standard endoscopic ventriculostomy was performed.^{2,14,15,17,18}

In all clinical cases, amplitudes of 60–80% were applied. Aspiration of soft pituitary adenoma tissue was achieved without difficulty or complications. The efficacy of the device was found to be good with reliable tissue aspiration in moderate velocity in 1 case (Grade 2 efficacy) and good to very good in the other case (Grade 2–3 efficacy). Intraventricular hematoma evacuation and cyst wall perforation were performed without any difficulties with 60–80% amplitudes (Fig. 5). The efficacy of the device was found to be good with reliable blood clot and craniopharyngioma cyst wall aspiration at moderate velocity setting in all 3 cases (Grade 2 efficacy). No complications occurred.

Conclusions

Neuroendoscopy has become an established, well-accepted treatment strategy for various pathological entities. For selected intra- and paraventricular tumors, endoscopy offers a treatment option that combines hydrocephalus treatment with tumor biopsy, or even with (often partial) tumor resection.^{8,9} However, minimally invasive endoscopic tumor removal is often limited by tumor size and vascularization.⁸ Endoscopic removal of solid tumors > 2-cm diameter

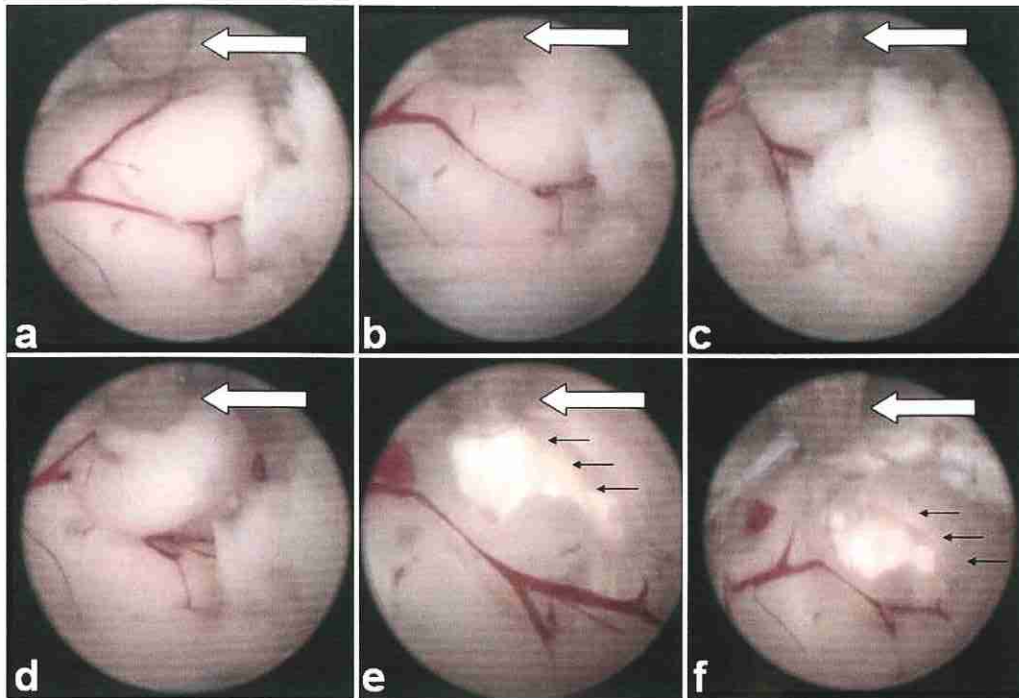


FIG. 3. Endoscopic views of porcine brain parenchyma ultrasonic aspiration at the lateral ventricular wall. A stepwise ultrasonic aspiration with slow circular hand movements allowing an effective tissue removal is shown. Aspirator tip is marked by white arrows and tissue resection area by black arrows.

is time consuming, and a switch to microsurgery is often required. The ultrasonic aspirator was first applied in neurosurgical procedures by Flamm and colleagues⁷ in 1978. Further modifications and improvements followed, and the ultrasonic aspirator became an important instrument for the removal of brain tumors.^{1,3-6,10,16} Thus, the application of an ultrasonic aspirator in neuroendoscopic procedures could effectively contribute to expand indications for neuroendoscopic procedures.

Here, we present our experimental and first clinical data with the application of a new ultrasonic aspirator handpiece under neuroendoscopic conditions. The new handpiece allowed the precise and effective aspiration of brain tissue in the cadaveric pig brain, and a close correlation of the applied amplitudes and the resulting aspiration depth was observed. No problems with blurring of vision in the operative field were noted. Under clinical conditions and particularly in intraventricular applications, aspiration of blood clots was

easy and effective. Thus, because bleeding is a rather frequent problem in neuroendoscopic procedures,^{8,9,14,18} and because larger solid intraventricular lesions are often difficult to remove even when almost nonvascularized (due to size alone),^{1,18} the ultrasonic aspirator tip may be useful in expanding the spectrum of endoscopic procedures. It remains to be seen whether this device can be used to aspirate firm meningiomas or calcified, fibrous tumors. Additionally, in pituitary tumor surgery, caution must be exercised with regard to the risk of carotid artery injury, pituitary gland damage, and diaphragm perforation until the safety of the device has been demonstrated.

This study is limited by its design, and is primarily intended to introduce the new device. No definitive conclusion on its potential can be reached, and further studies are required to determine its usefulness in the daily clinical routine.

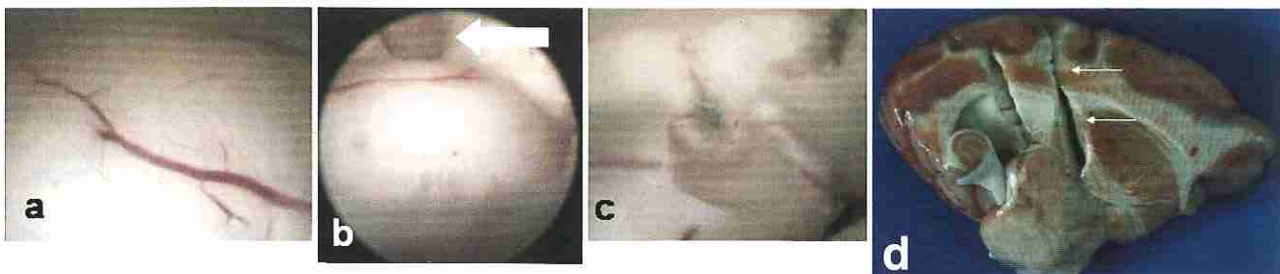


FIG. 4. Views of porcine brain parenchyma ultrasonic aspiration at the lateral ventricular wall. a-c: Endoscopic views of stepwise ultrasonic aspiration with slow circular hand movements allowing an effective tissue removal are shown. Aspirator tip is marked by a large white arrow. d: Photograph of cadaveric specimen with tissue aspiration defects. Tissue resection area is marked by small white arrows.

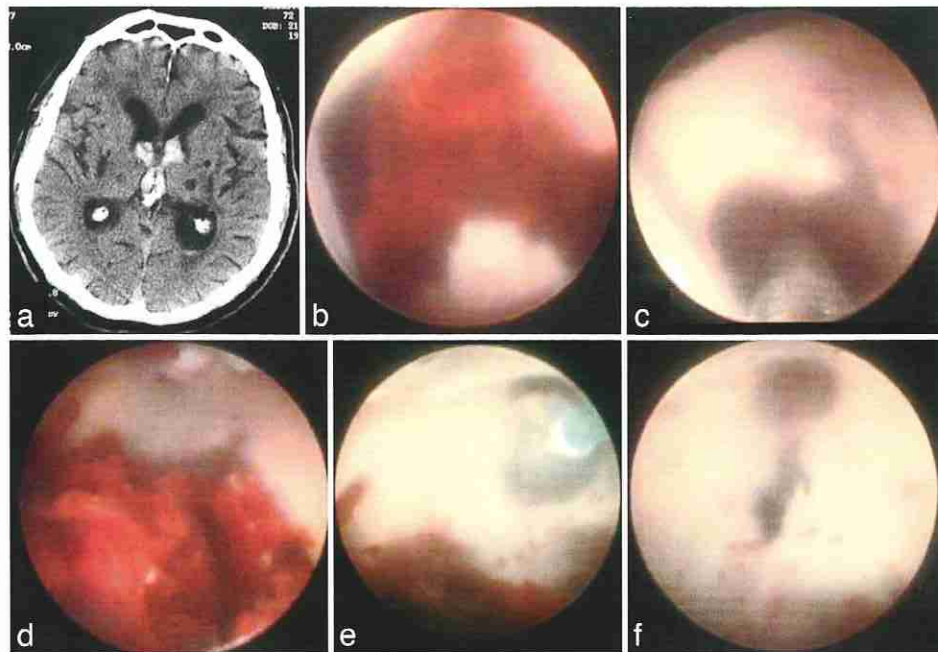


FIG. 5. a: Preoperative CT scan in a patient with obstructive hydrocephalus due to intraventricular hemorrhage. Occlusion of the third ventricle by the hematoma is shown. b: Endoscopic view at the foramen of Monro filled with intraventricular hematoma. c: Hematoma aspiration with the ultrasonic aspirator handpiece. d: View of the floor of the third ventricle. e: Ventriculostomy enlargement with a balloon catheter. f: Results after endoscopic third ventriculostomy at the floor of the third ventricle.

Disclosure

Dr. Michael R. Gaab is a consultant to Karl Storz GmbH & Co. The authors state that they have no further interest in the methodology or equipment advanced in this report. This study was supported by a grant of the Else Kroener Fresenius Stiftung, Bad Homburg, Germany.

Acknowledgments

We thank Dr. Michael Gen for his expert support during the experimental parts of this study, and Mrs. Schuster and Mr. Wittek for expert technical assistance.

References

- Albright AL, Scabassi RJ: Use of the Cavitron ultrasonic surgical aspirator and evoked potentials for the treatment of thalamic and brain stem tumors in children. *Neurosurgery* **17**:564–568, 1985
- Baldauf J, Oertel J, Gaab MR, Schroeder HW: Endoscopic third ventriculostomy for occlusive hydrocephalus caused by cerebellar infarction. *Neurosurgery* **59**:539–544, 2006
- Brock M, Ingwersen I, Roggendorf W: Ultrasonic aspiration in neurosurgery. *Neurosurg Rev* **7**:173–177, 1984
- Chen TC, Rabb C, Apuzzo ML: Complex technical methodologies and their applications in the surgery of intracranial meningiomas. *Neurosurg Clin North Am* **5**:261–281, 1994
- Day JD, Fukushima T: Suction control of ultrasonic aspirators. *J Neurosurg* **78**:688–689, 1993
- Egemen N: Suction control attachment for ultrasonic aspirators: Technical note. *J Neurosurg* **77**:316–317, 1992
- Flamm ES, Ransohoff J, Wuchinich D, Broadwin A: Preliminary experience with ultrasonic aspiration in neurosurgery. *Neurosurgery* **2**:240–245, 1978
- Gaab MR, Schroeder HWS, Oertel J: Neuroendoscopic approach to intraventricular tumors, in Schmidek HH, Sweet WH (eds): *Operative Neurosurgical Techniques. Indications, Methods, and Results*, ed 5. Philadelphia: WB Saunders, 2006, pp 739–752
- Hellwig D, Grotenhuis JA, Tirakotai W, Riegel T, Schulte

- DM, Bauer BL, et al: Endoscopic third ventriculostomy for obstructive hydrocephalus. *Neurosurg Rev* **28**:1–34, 2005
- Jallo GI: CUSA EXcel ultrasonic aspiration system. *Neurosurgery* **48**:695–697, 2001
- Oertel J, Gaab M: Endoscopic endonasal transsphenoidal approach to sellar lesions: a detailed account of our technique, in Meixenburger J (ed): *Abstractband der 58. Jahrestagung der Deutschen Gesellschaft für Neurochirurgie*. Leipzig: Himmer Gmbh & Co. KG, 2007, p 19
- Oertel J, Gaab MR, Pillich DT, Schroeder HW, Warzok R, Piek J: Comparison of waterjet dissection and ultrasonic aspiration: an in vivo study in the rabbit brain. *J Neurosurg* **100**:498–504, 2004
- Oertel J, Gaab MR, Runge U, Schroeder HW, Piek J: Waterjet dissection versus ultrasonic aspiration in epilepsy surgery. *Neurosurgery* **56** (1 Suppl):142–146, 2005
- Oertel J, Gen M, Krauss JK, Zumkeller M, Gaab MR: The use of waterjet dissection in endoscopic neurosurgery. Technical note. *J Neurosurg* **105**:928–931, 2006
- Oertel J, Schroeder HW, Gaab MR: Third ventriculostomy for treatment of hydrocephalus: results of 271 procedures. *Neurosurg Q* **16**:24–31, 2006
- Sawamura Y, Fukushima T, Terasaka S, Sugai T: Development of a handpiece and probes for a microsurgical ultrasonic aspirator: instrumentation and application. *Neurosurgery* **45**:1192–1196, 1999
- Schroeder HW, Oertel J, Gaab MR: Endoscopic treatment of cerebrospinal fluid pathway obstructions. *Neurosurgery* **60** (2 Suppl):44–52, 2007
- Schroeder HW, Oertel J, Gaab MR: Incidence of complications in neuroendoscopic surgery. *Childs Nerv Syst* **20**:878–883, 2004

Manuscript submitted December 4, 2007.

Accepted March 10, 2008.

Address correspondence to: Joachim Oertel, M.D., Ph.D., Department of Neurosurgery, Nordstadt-Krankenhaus, Klinikum Region Hannover, Haltenhoffstrasse 41, 30167 Hannover, Germany. email: oertelj@freenet.de.