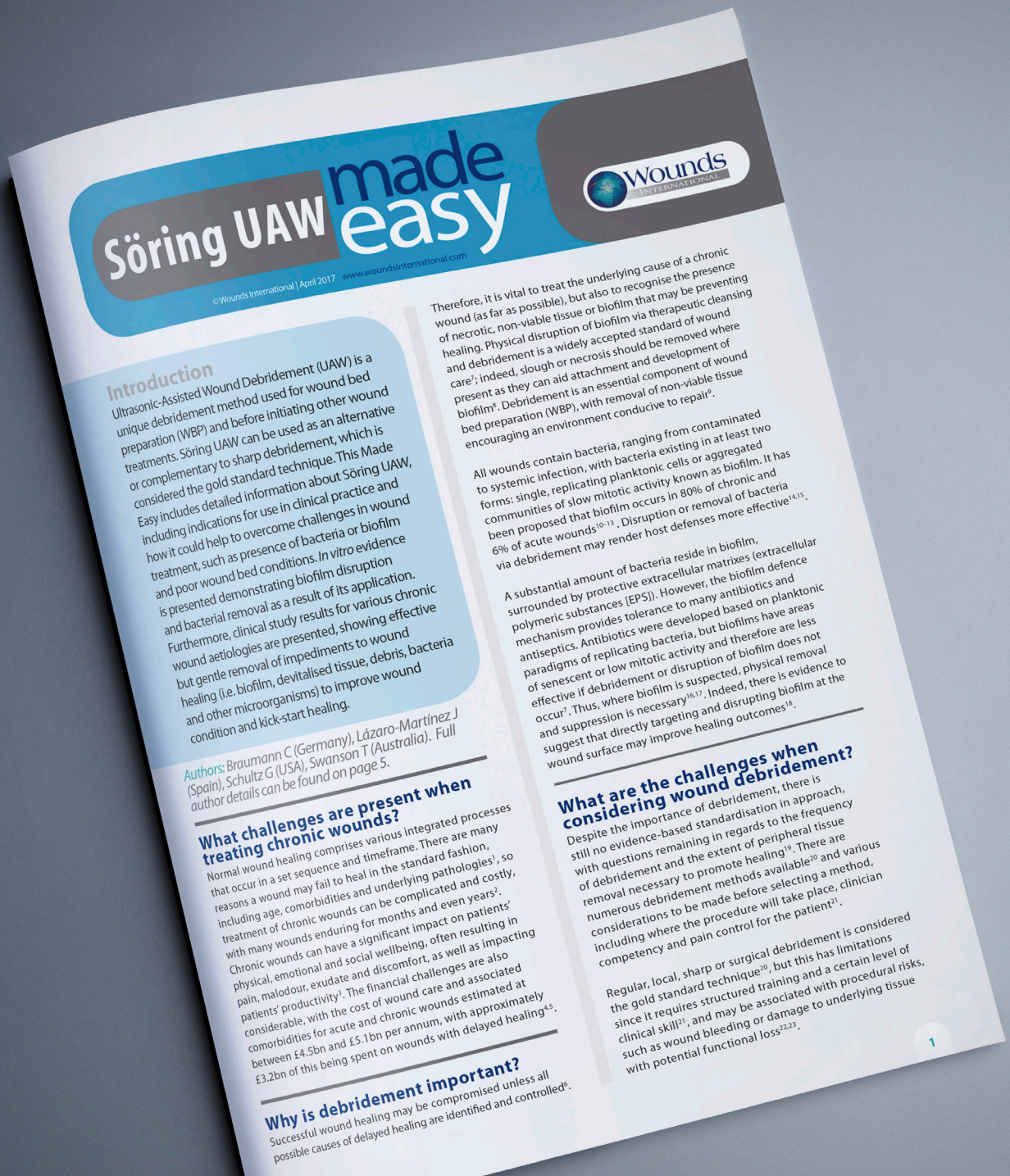




Quickfinder: Söring UAW made easy



Söring UAW made easy



© Wounds International | April 2017 www.woundsinternational.com

Introduction

Ultrasonic-Assisted Wound Debridement (UAW) is a unique debridement method used for wound bed preparation (WBP) and before initiating other wound treatments. Söring UAW can be used as an alternative or complementary to sharp debridement, which is considered the gold standard technique. This Made Easy includes detailed information about Söring UAW, including indications for use in clinical practice and how it could help to overcome challenges in wound treatment, such as presence of bacteria or biofilm and poor wound bed conditions. In vitro evidence is presented demonstrating biofilm disruption and bacterial removal as a result of its application. Furthermore, clinical study results for various chronic wound aetiologies are presented, showing effective but gentle removal of impediments to wound healing (i.e. biofilm, devitalised tissue, debris, bacteria and other microorganisms) to improve wound condition and kick-start healing.

Authors: Braumann C (Germany), Lázaro-Martínez J (Spain), Schultz G (USA), Swanson T (Australia). Full author details can be found on page 5.

What challenges are present when treating chronic wounds?

Normal wound healing comprises various integrated processes that occur in a set sequence and timeframe. There are many reasons a wound may fail to heal in the standard fashion, including age, comorbidities and underlying pathologies¹, so treatment of chronic wounds can be complicated and costly, with many wounds enduring for months and even years². Chronic wounds can have a significant impact on patients' physical, emotional and social wellbeing, often resulting in pain, malodour, exudate and discomfort, as well as impacting patients' productivity³. The financial challenges are also considerable, with the cost of wound care and associated comorbidities for acute and chronic wounds estimated at between £4.5bn and £5.1bn per annum, with approximately £3.2bn of this being spent on wounds with delayed healing^{4,5}.

Why is debridement important?

Successful wound healing may be compromised unless all possible causes of delayed healing are identified and controlled⁶.

Therefore, it is vital to treat the underlying cause of a chronic wound (as far as possible), but also to recognise the presence of necrotic, non-viable tissue or biofilm that may be preventing healing. Physical disruption of biofilm via therapeutic cleansing and debridement is a widely accepted standard of care⁷; indeed, slough or necrosis should be removed where present as they can aid attachment and development of biofilm⁸. Debridement is an essential component of wound bed preparation (WBP), with removal of non-viable tissue encouraging an environment conducive to repair⁹.

All wounds contain bacteria, ranging from contaminated to systemic infection, with bacteria existing in at least two forms: single, replicating planktonic cells or aggregated communities of slow mitotic activity known as biofilm. It has been proposed that biofilm occurs in 80% of chronic and 6% of acute wounds¹⁰⁻¹³. Disruption or removal of bacteria via debridement may render host defenses more effective^{4,15}.

A substantial amount of bacteria reside in biofilm, surrounded by protective extracellular matrices (extracellular polymeric substances [EPS]). However, the biofilm defence mechanism provides tolerance to many antibiotics and antiseptics. Antibiotics were developed based on planktonic paradigms of replicating bacteria, but biofilms have areas of senescent or low mitotic activity and therefore are less effective if debridement or disruption of biofilm does not occur⁷. Thus, where biofilm is suspected, physical removal and suppression is necessary^{16,17}. Indeed, there is evidence to suggest that directly targeting and disrupting biofilm at the wound surface may improve healing outcomes¹⁸.

What are the challenges when considering wound debridement?

Despite the importance of debridement, there is still no evidence-based standardisation in approach, with questions remaining in regards to the frequency of debridement and the extent of peripheral tissue removal necessary to promote healing¹⁹. There are numerous debridement methods available²⁰ and various considerations to be made before selecting a method, including where the procedure will take place, clinician competency and pain control for the patient²¹.

Regular, local, sharp or surgical debridement is considered the gold standard technique²⁰, but this has limitations since it requires structured training and a certain level of clinical skill²¹, and may be associated with procedural risks, such as wound bleeding or damage to underlying tissue with potential functional loss^{22,23}.

→ Content: Söring UAW made easy

This “Quickfinder” document is a tool which helps you to find a specific topic or buzz word within the „Söring UAW made easy“. The following overview includes the most important aspects of the made easy content sorted by page numbers. If you are interested in e.g. the “**Evidence** overview” on page 3, you can jump directly to the respective text passage by clicking at the button located behind. Once you’re done reading the passage, one click on the home-button at the bottom of every page will bring you back to the overview where you can look for the next buzz word.

1
Page
2
3
4
5
6

- **Aftermath and challenges of chronic wounds**
- **Why is a debridement important**
- **Biofilm and its relevance for wounds**
- **Risks of the gold standard; the surgical debridement**
- **Specialties of Söring UAW**
- **Cavitation or rather UAW's mode of action**
- **Illustration of cavitation**
- **Case Study of UAW for diabetic foot ulcers (DFU)**
- **Indications for Söring UAW**
- **Effectiveness of UAW against biofilm**
- **Advantages of UAW over surgical debridement**
- **Evidence overview**
- **UAW & PHMB antiseptic part of biofilm based wound care**
- **DFU debridement option: UAW**
- **Limitations of alternative debridement options for DFU**
- **Post-surgical wounds with UAW**
- **Case Study UAW for post-surgical wounds**
- **Pain management while using UAW**
- **Aerosol countermeasures**
- **Cost benefits of Söring UAW**
- **References overview**
- **Conclusion**



Introduction

Ultrasonic-Assisted Wound Debridement (UAW) is a unique debridement method used for wound bed preparation (WBP) and before initiating other wound treatments. Söring UAW can be used as an alternative or complementary to sharp debridement, which is considered the gold standard technique. This Made Easy includes detailed information about Söring UAW, including indications for use in clinical practice and how it could help to overcome challenges in wound treatment, such as presence of bacteria or biofilm and poor wound bed conditions. *In vitro* evidence is presented demonstrating biofilm disruption and bacterial removal as a result of its application. Furthermore, clinical study results for various chronic wound aetiologies are presented, showing effective but gentle removal of impediments to wound healing (i.e. biofilm, devitalised tissue, debris, bacteria and other microorganisms) to improve wound condition and kick-start healing.

Authors: Braumann C (Germany), Lázaro-Martínez J (Spain), Schultz G (USA), Swanson T (Australia). Full author details can be found on page 5.

What challenges are present when treating chronic wounds?

Normal wound healing comprises various integrated processes that occur in a set sequence and timeframe. There are many reasons a wound may fail to heal in the standard fashion, including age, comorbidities and underlying pathologies¹, so treatment of chronic wounds can be complicated and costly, with many wounds enduring for months and even years². Chronic wounds can have a significant impact on patients' physical, emotional and social wellbeing, often resulting in pain, malodour, exudate and discomfort, as well as impacting patients' productivity³. The financial challenges are also considerable, with the cost of wound care and associated comorbidities for acute and chronic wounds estimated at between £4.5bn and £5.1bn per annum, with approximately £3.2bn of this being spent on wounds with delayed healing^{4,5}.

Why is debridement important?

Successful wound healing may be compromised unless all possible causes of delayed healing are identified and controlled⁶.

Therefore, it is vital to treat the underlying cause of a chronic wound (as far as possible), but also to recognise the presence of necrotic, non-viable tissue or biofilm that may be preventing healing. Physical disruption of biofilm via therapeutic cleansing and debridement is a widely accepted standard of wound care⁷; indeed, slough or necrosis should be removed where present as they can aid attachment and development of biofilm⁸. Debridement is an essential component of wound bed preparation (WBP), with removal of non-viable tissue encouraging an environment conducive to repair⁹.

All wounds contain bacteria, ranging from contaminated to systemic infection, with bacteria existing in at least two forms: single, replicating planktonic cells or aggregated communities of slow mitotic activity known as biofilm. It has been proposed that biofilm occurs in 80% of chronic and 6% of acute wounds¹⁰⁻¹³. Disruption or removal of bacteria via debridement may render host defenses more effective^{14,15}.

A substantial amount of bacteria reside in biofilm, surrounded by protective extracellular matrixes (extracellular polymeric substances [EPS]). However, the biofilm defence mechanism provides tolerance to many antibiotics and antiseptics. Antibiotics were developed based on planktonic paradigms of replicating bacteria, but biofilms have areas of senescent or low mitotic activity and therefore are less effective if debridement or disruption of biofilm does not occur⁷. Thus, where biofilm is suspected, physical removal and suppression is necessary^{16,17}. Indeed, there is evidence to suggest that directly targeting and disrupting biofilm at the wound surface may improve healing outcomes¹⁸.

What are the challenges when considering wound debridement?

Despite the importance of debridement, there is still no evidence-based standardisation in approach, with questions remaining in regards to the frequency of debridement and the extent of peripheral tissue removal necessary to promote healing¹⁹. There are numerous debridement methods available²⁰ and various considerations to be made before selecting a method, including where the procedure will take place, clinician competency and pain control for the patient²¹.

Regular, local, sharp or surgical debridement is considered the gold standard technique²⁰, but this has limitations since it requires structured training and a certain level of clinical skill²¹, and may be associated with procedural risks, such as wound bleeding or damage to underlying tissue with potential functional loss^{22,23}.

Why debridement

Biofilm relevance

Gold standard risks

Söring UAW made easy



Specialties of UAW

Söring UAW: What makes the difference?

Söring Ultrasonic-Assisted Wound Debridement (UAW) is a gentle wound debridement and cleansing method, which uses low-frequency ultrasound oscillations of 25 kHz²⁴, allowing for easy removal of soft non-viable tissue²⁵, disruption of biofilm²⁶ and WBP before initiation of advanced wound treatment²⁷. Clinical experiences with Söring UAW for WBP prior to skin grafting to achieve wound closure have shown it to be relatively painless and bloodless, with potential for cost savings if amputations and antibiotics are avoided²⁸.

Söring UAW is also a viable option for wounds with limitations such as poor vascular status, or exposed bone, ligaments or joints, where surgical debridement would cause extensive damage^{29,30}. Indications from clinical practice have shown that debridement with Söring UAW provides selective removal of devitalised tissue without damaging intact cells at the wound site and prepares the wound environment to kick-start healing. Post-debridement, wounds have been described as 'vital and vivid'³¹.

Cavitation

How does Söring UAW work?

Söring UAW has a selective mode of action that can be explained via the effects of cavitation and microstreaming, which are caused by vibrations of an ultrasound probe (sonotrode) at 25 kHz in an irrigation solution (Figure 1).

Cavitation is a phenomenon caused by an oscillating probe in a fluid medium creating microbubbles that form and vibrate to disrupt and debride tissue³². When these cavitation bubbles collapse, a jet-like injection into the fluid occurs, which has a mechanical effect on surrounding biomaterial or tissue. In clinical, low-frequency ultrasound device applications, these mechanical effects are tissue-selective, with selectivity resulting from tissue strength, determined primarily by amount, type and organisation of collagen fibres^{33,34}: the more well organised the collagen fibres, the stronger the tissue^{34,35}.

Debridement with Söring UAW exerts a different effect on damaged tissues versus healthy tissues, ensuring that devitalised tissues, foreign bodies and biofilm are efficiently debrided, while the surrounding healthy tissue is hardly affected²⁹.

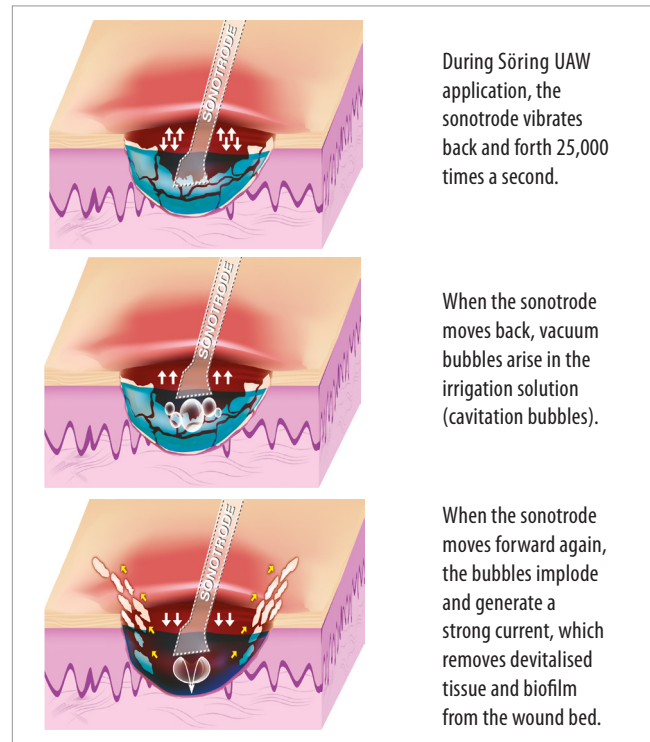
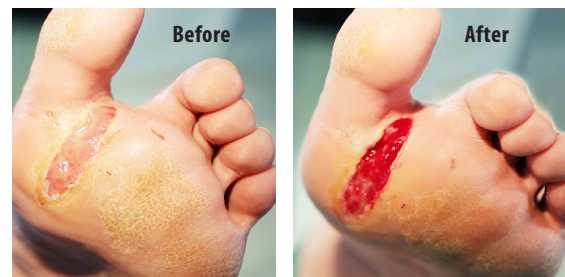

Figure 1: Söring UAW's unique mode of action

Cavitation illustration

Case Study 1: 60-year-old male with a diabetic foot ulcer that developed after an accident at work resulting in a phlegmon of the lower extremity.



Case Study 2: 73-year-old male with a pressure ulcer at the right heel as a consequence of peripheral angiopathy due to diabetes.

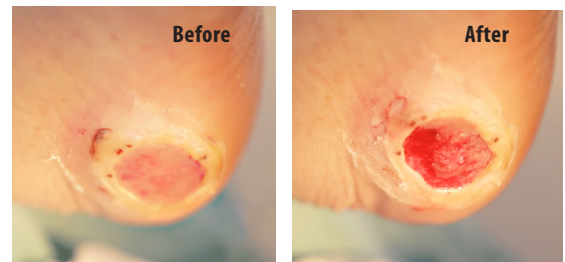


Figure 2: Effective removal of devitalised tissue and creation of a viable wound bed for a DFU and a pressure ulcer using Söring UAW

Case study DFU



What are the indications for Söring UAW?

Söring UAW can be used for various chronic wound types that would benefit from debridement, including diabetic foot ulcers (DFUs), locally infected wounds, pressure injuries and venous leg ulcers (VLUs)²⁹. Examples of Söring UAW in use are given in [Figure 2](#). Söring UAW can be applied to numerous wound locations using different instruments (with different sonotrodes) ([Figure 3](#)), including areas that are difficult-to-reach (i.e. between the toes)⁴¹. Söring UAW is not effective for very hard eschar, so conservative sharp debridement should be conducted first or as an adjunct in such instances.

What evidence is available for Söring UAW?

A range of evidence exists supporting the efficacy and cost-effectiveness of Söring UAW, including *in vitro* data, numerous case studies and a randomised controlled trial (RCT):

- **In vitro data:** Application of 10 seconds of moderate-intensity Söring UAW effectively disrupted semi-solid biofilm. A reduction in the number of viable bacteria was seen when using Söring UAW before applying

polyhexamethylene biguanide (PHMB) solution. Applying Söring UAW in the presence of PHMB provided further antibacterial efficacy of the PHMB solution²⁶.

- **RCT evidence:** In a monocentric, prospective RCT involving patients with VLUs, the efficacy, tolerability and patient benefits of Söring UAW were compared with surgical wound debridement. Results showed Söring UAW was as effective and safe, but with a significantly better quality of life and risk profile, than surgical wound debridement. Söring UAW was a time-saving alternative to wound cleansing in the operating theatre, with delegation to trained healthcare professionals possible due to the procedure's simplicity. As such, Söring UAW has the potential to reduce direct staff costs. Moreover, patient acceptance is high and the procedure can be performed on an outpatient basis²⁴.
- **Other:** Further evaluations are presented in [Table 1](#).

Clinician experiences with Söring UAW

Wounds presenting with biofilm

Biofilm-based wound care strategies include preventative actions that interfere with microbial attachment and biofilm maturation processes, as well as attacking existing communities, removing or disrupting maturing biofilm and

Reference	Study type	Outcomes
Lázaro-Martínez et al, 2015 ³⁶	Pilot study	In a case series involving patients with complicated DFUs, sequential wound debridement with Söring UAW used in combination with a super-oxidised solution led to safe and effective wound cleansing, removal of biofilm and reduction of bacteria, thus controlling wound infection. After Söring UAW debridement, faster granulation was seen and healing of wounds was kick-started.
Lázaro-Martínez et al, 2016(a) ³⁰	Monocentric, controlled clinical study	Sequential wound debridement with Söring UAW led to reduction in bacterial load immediately after debridement and cumulatively across the treatment period. Debridement with UAW appeared to prevent biofilm reformation. The measured effects of Söring UAW were the same irrespective of bacterial species, including resistant strains. Improved granulation was seen, resulting from a changed, healing-friendly wound environment.
Lázaro-Martínez et al, 2016(b) ³⁷	Monocentric, controlled clinical study	Sequential wound debridement of neuroischaemic DFUs with Söring UAW in combination with super-oxidised solution reduced bacterial load and improved wound condition. Measured effects were the same irrespective of bacterial species, including resistant strains.
Yarets et al, 2013 ³⁸	Comparative analysis	In ulcers of mixed aetiologies, a change in the dynamics of biofilm formation (<i>Staphylococcus aureus</i>) towards less production of biofilm substance was seen for bacteria derived from wounds debrided with Söring UAW before skin grafting.
Yarets et al, 2015 ³⁹	Follow-up comparative analysis	When evaluating the efficacy of one or two Söring UAW debridement sessions prior to skin grafting, a change in the dynamics of biofilm formation (<i>Staphylococcus aureus</i> and <i>Pseudomonas aeruginosa</i>) in bacteria derived from wounds debrided with Söring UAW was detected. In colonised wounds, application of two Söring UAW sessions prior to skin grafting increased the potential take-rate to 100%.
Hoffman et al, 2016 ⁴⁰	Preliminary study	Preliminary results from patients with venous and arterial leg ulcers showed Söring UAW to be efficacious at cleaning wounds and removing biofilms, thus kick-starting healing. Söring UAW was easy for medical practitioners and attendant nurses to use.

Table 1: Evaluations of Söring UAW




Figure 3: Söring UAW sonotrodes for debridement of different types of wound



preventing its reformation⁷. Söring UAW is an important option that mechanically breaks up biofilm. An *in vitro* model demonstrated that applying Söring UAW with a PHMB antiseptic (either before or in the presence of PHMB) disrupted semi-solid biofilm and significantly reduced the number of viable bacteria present. Thus, Söring UAW with PHMB antiseptic has potential as part of a biofilm-based wound care strategy²⁶.

Diabetic foot ulcers

Management of DFUs is based on repeated debridement, frequent inspection to monitor infection and control of bacteria and moisture management⁴². Debridement may be needed as a one-off or maintenance may be required. Where wounds are not progressing as expected, clinicians should assess the underlying cause of delayed healing and review the patient's treatment plan accordingly, looking at vascular status, presence of infection – especially underlying osteomyelitis – and offloading strategies.

Options for DFU debridement include sharp or autolytic debridement, larval therapy and, in recent years, ultrasonic therapy⁴³. The choice of debridement method should be based on the available expertise, patient preferences, clinical context and cost. Surgical and sharp debridement can be carried out by experienced, trained clinicians but should be used with caution in patients with ischaemic foot. One limitation of sharp debridement is that it is usually conducted at treatment commencement and may not be repeated for new tissue. Other limitations can include: poor vascular status; the requirements for surgeon skill and an operating theatre location; and risk of damage to the wound bed, where bone, ligaments or joints are exposed. Moreover, conservative options based on autolytic and larval debridement are usually slow and limited³⁷.

Söring UAW is a simple and safe alternative for removal of slough and non-viable tissue for DFUs. It can be used without anesthesia in many cases due to diabetic neuropathy and does not require a surgical ward. Furthermore, it may be performed in ischaemic patients for whom surgical procedures are contraindicated.

Post-surgical wounds

Successful treatment of post-surgical wounds with healing disorders requires assessment of the entire patient and treatment of systemic problems impairing wound healing. There are many causes for non-healing post-surgical wounds; probably the most common is infection, known as surgical site infection (SSI)⁴⁴. The presence of underlying systemic conditions can decrease immune function and complicate

healing. For example, patients with poor nutritional status and/or diabetes mellitus have an increased risk of SSIs and post-surgical wound healing disorders, and cancer patients are also at high risk. Another risk derives from operations involving the intestines, which have a higher rate of SSIs due to the levels of bacteria present. Furthermore, certain surgical techniques may contribute to higher infection rates^{45,46}.

As with other non-healing wounds, underlying diseases and the patient's medical condition should be properly controlled. Antibiotics may be given if necessary⁴⁷, but this should be in conjunction with debridement if not contraindicated to enhance efficacy. Debridement is considered an integral part of care for wounds showing post-surgical healing disorders, to remove debris, bacteria and fibrin deposits that may be impeding wound healing^{16,17,48}. Benefits to be derived from Söring UAW include the possibility of ambulatory treatment for patients considered at risk for developing post-surgical wound disorders. Clinicians can treat post-surgical complications and remove impediments to wound healing without hospitalisation and the patient's condition can be re-established while they continue activities of daily living.

First clinical experiences with Söring UAW have shown that it is essential to consider wound condition before debriding. Wounds must be assessed for size and depth, involvement and extent of undermining, appearance and status of the tissues at the wound surface (necrotic or viable), amount and characteristics of exudate and periwound condition. In post-surgical wounds with healing disorders, it is essential to be precise during the procedure to avoid causing the patient any pain.

Figure 4 shows a sacral wound before and 3 minutes after Söring UAW debridement. Before debridement, the wound has fibrin depositions, debris and probable bacteria and biofilm. After debridement, the wound bed is clean with no fibrin depositions, has a homogenous surface with healthy and well vascularised tissue, and clearly defined wound margins.

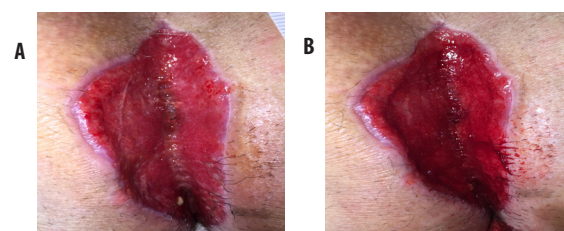


Figure 4: Sacral wound with post-surgical wound healing disorder before (A) and after debridement (B) with Söring UAW

How to use Söring UAW

The low-frequency ultrasound vibrations are generated by an ultrasonic generator (SONOCA) and piezo electronics inside the Söring UAW instrument. There are three Söring UAW instruments (with different sonotrodes) for the purpose of contact debridement, which are lightweight and ergonomic in design for precise control and reduced practitioner hand-fatigue. These also provide versatility across wound types and locations⁴¹. Söring UAW requires appropriate education under the supervision of a trained operator²⁹, but can be undertaken by healthcare professionals of various disciplines, and the procedure does not need to take place inside the operating theatre⁴⁰.

Söring UAW in daily practice

Managing pain

For patients experiencing pain, or in anticipation of eliciting discomfort, analgesic creams are effective with sufficient time and dosage. These can be applied by staff, patients or caregivers, depending on circumstances, and the patient may also be encouraged to take a simple analgesic 45 minutes before treatment takes place. For patients who have very painful wounds, increasing the flow of irrigation and/or decreasing ultrasonic intensity during the procedure may help. Non-contact treatment may be attempted if these approaches fail, by hovering as close to the wound as the patient will allow.

Setting up and using the device

Although set up and application of Söring UAW is very simple, only trained or registered staff should use the device. Set up and treatment can be conducted as a solo clinician but must be sequenced if using a surgical aseptic technique to avoid contamination of the field. The system's generator requires a power supply and therefore the system must be used in an environment with an electrical output. The aerosolisation of

BOX 1: UAW CLEARSHIELD

UAW ClearShield is a soft, flexible silicone cap designed to reduce the spread of splashes and mist during application of Söring UAW. It keeps airborne particles inside its boundaries, enhancing convenience during application and lowering the amount of wipe-disinfection required after treatment, thus enabling more widespread use of Söring UAW.



fluid during Söring UAW is associated with potential spread of microorganisms, so incurs infection control requirements.

Personal protective equipment for the healthcare professional and patient is important, and if visitors are present, their safety should also be considered. It must be possible to 'wipe down' all surfaces in the treatment room with a detergent or antimicrobial cleanser. Suction machines and adapters can be used, but these add to cost, weight and storage requirements. Alternatively, an additional accessory to overcome aerosolisation concerns has recently been developed, as shown in [Box 1](#).

Patient consent and education

Informed consent must be obtained prior to treatment and placed in the patient record. Simple verbal and written education about Söring UAW should be given to the patient, or demonstrations may be provided; for instance, it can be helpful to show the mist that is produced when explaining how the procedure works.

What are the cost benefits of Söring UAW?

Once the Söring UAW device is purchased, ongoing costs are minimal as the instruments can be reprocessed and reused. Required equipment includes tubing, irrigation solution (sterile saline or antiseptic), dressing tray, protective equipment and topical anaesthetic products. As such, the overall cost per treatment, including staff time, consumables and dressings is approximately £118, of which only £20 is related to Söring UAW consumables²⁹. The evidence presented in this *Made Easy* demonstrates that Söring UAW effectively removes non-viable tissue and biofilm, even in difficult-to-reach areas, which enhances wound healing. In addition to the demonstrated clinical benefits, the instruments used for this procedure are completely reprocessable and can be used by a variety of healthcare professionals²⁹, thus making Söring UAW a cost-effective and timely option for chronic wound debridement.

Supported by an educational grant from Söring. The views expressed in this *Made Easy* do not necessarily reflect those of Söring.

Author details

Braumann C¹, Lázaro-Martínez J², Schultz G³, Swanson T⁴

1. Dr. Chris Braumann, General Surgeon and Visceral Surgeon, Surgical Clinic, St. Josef-Hospital Bochum, Germany
2. Prof. José Luis Lázaro-Martínez, Profesor Titular de Universidad, Universidad Complutense de Madrid, Spain
3. Prof. Greg Schultz, Institute for Wound Research, Department of Obstetrics and Gynaecology, University of Florida, USA
4. Terry Swanson, Nurse Practitioner Wound Management, South West Healthcare, Warrnambool, Victoria, Australia

References

- Harding K. Wounds and wound healing: new insights, fresh challenges. *Br J Dermatol* 2015; 173(2): 318–9
- Dowsett C. Breaking the cycle of hard-to-heal wounds: balancing cost and care. *Wounds International* 2015; 6(2): 17–21
- Vowden K, Vowden P. *Debridement Made Easy*. 2011. Available from: http://www.wounds-uk.com/pdf/content_10133.pdf (accessed 04.01.16)
- Guest JF, Ayoub N, Mcllwraith T, et al. Health economic burden that wounds impose on the national health service in the UK. *BMJ Open* 2015; 5: 12, e009283
- Guest JF, Ayoub N, Mcllwraith T, et al. Health economic burden that different wound types impose on the UK's national health service. *Int Wound J* 2017; 14(2): 322–30
- Leaper DJ, Shultz G, Carville K, et al. Extending the TIME concept: what have we learned in the past 10 years? *Int Wound J* 2012; 9(Suppl 2): 1–19
- World Union of Wound Healing Societies (WUWHS), Florence Congress. *Position Document. Management of Biofilm*. Wounds International, 2016. Available from: www.woundsinternational.com (accessed 04.01.17)
- Percival S, Suleman L. Slough and biofilm: removal of barriers to wound healing by desloughing. *J Wound Care* 2015; 24(11): 498–510
- Gray D, Acton C, Chadwick P. Consensus guidance for the use of debridement techniques in the UK. *Wounds UK* 2011; 7(1): 77–84
- Kirketerp-Moeller K, Jensen PO, Fazli M, et al. Distribution, organization, and ecology of bacteria in chronic wounds. *J Clin Microbiol* 2008; 46(8): 2712–22
- James GA, Swogger E, Wolcott R, et al. Biofilms in chronic wounds. *Wound Repair Regen* 2008; 16(1): 37–44
- Wu S, Skratsky M. Debridement and the current state of play. *Podiatry Management* 2012; 145–51
- Malone M, Bjarnsholt T, McBain A, et al. The prevalence of biofilms in chronic wounds: a systematic review and meta-analysis of published data. *J Wound Care* 2016; 25(12): 1–5
- Cardinal M, Eisenbud D, Armstrong D, et al. Serial surgical debridement: A retrospective study on clinical outcomes in chronic lower extremity wounds. *Wound Rep Reg* 2009; 17(3): 306–11
- Piaggese A, Schipani E, Campi F, et al. Conservative surgical approach versus non-surgical management for diabetic neuropathic foot ulcers: A randomized trial. *Diabet Med* 1998; 15(5): 412–7
- Schultz GS, Sibbald RG, Falanga V, et al. Wound bed preparation: a systemic approach to wound management. *Wound Repair Regen* 2013; 11(Suppl 1): S1–28
- Kirshen C, Woo K, Ayello E, et al. Debridement: a vital component of wound bed preparation. *Adv Skin Wound Care* 2006; 19(9): 506–17
- Wolcott R. Disrupting the biofilm matrix improves wound healing outcomes. *J Wound Care* 2015; 24(8): 366–71
- Strohler R, Apelqvist J, Dissemond J, et al. EWMA Document: Debridement. *J Wound Care* 2013; 22 (Suppl1): S1–52
- Vowden K, Vowden P. The economic impact of hard-to-heal wounds: promoting practice change to address passivity in wound management. *Wounds International* 2016; 7(2): 10–5
- Leak K. Top ten tips for wound debridement. *Wounds International* 2012 3(1): 21–3
- Steed DL. Debridement. *Am J Surg* 2004; 187(5a): S71–74
- Falabella AF. Debridement and wound bed preparation. *Dermatol Ther* 2006; 29(6): 317–25
- Herberger K, Franzke N, Blome C, et al. Efficacy, tolerability and patient benefit of ultrasound-assisted wound treatment versus surgical debridement: a randomized clinical study. *Dermatology* 2011; 222(3): 244–9
- Schulze C, Breuing K, Bockholt C, et al. *Low-Frequency Ultrasonic Debridement Causes Disruption of Bacterial Biofilms and Restores Antibacterial Activity of Wound Antiseptic Substances In Vitro*. Paper presented at EWMA, September 2005, Stuttgart, Germany
- Crone S, Garde C, Bjarnsholt T, et al. A novel in vitro wound biofilm model used to evaluate low-frequency ultrasound-assisted wound debridement. *J Wound Care* 2015; 24(2): 64, 66–9, 72
- Bruno A, Schmidt B, Blume P. *Ultrasonic Debridement for Wounds: Where Are We Now?* Available from: <http://www.podiatrytoday.com/ultrasonic-debridement-wounds-where-are-we-now> (accessed 04.01.16)
- Breuning KH, Bayer L, Neuwalder J, et al. Early experience using low-frequency ultrasound in wounds. *Ann Plast Surg* 2005; 55(2):183–7
- Butcher G, Pinnuck L. Wound bed preparation: ultrasonic-assisted debridement. *Br J Nurs* 2013; 22(6): S36, S38–43
- Lázaro-Martínez JL, Álvaro-Afonso FJ, García-Álvarez Y, et al. *Improved Wound Conditions and Reduced Bacterial Load as a Result of Sequential Low-Frequency Ultrasonic Wound Debridement in Neuroischemic Diabetic Foot Ulcer*. Poster presented at SAWC, April 2016(a), Atlanta, US
- Gächter B. *Use of Low-Frequency Ultrasound on Patients With a Chronic Wound Healing Disorder*. Oral presentation at EWMA, May 2016, Bremen, Germany
- Voigt J, Wendelke M, Driver V, et al. Low-frequency ultrasound (20–40kHz) as an adjunctive therapy for chronic wound healing: A systematic review of the literature and meta-analysis of eight randomized controlled trials. *Int J Extrem Wound* 2011; 10(4): 190–9
- Cimino WW, Bond LJ. Physics of ultrasonic surgery using tissue fragmentation. *Ultrasound Med Biol* 1996; 22: 89–100
- Chan KK, Watmough DJ, Hope DT, et al. A new motor driven surgical probe and its in vitro comparison with the cavitation ultrasonic surgical aspirator. *Ultrasound Med Biol* 1986; 12: 279–83
- Amso NN. Applications of therapeutic ultrasound in medicine. *Ultrasonics Sonochem* 1994; 1: 569–71
- Lázaro-Martínez JL, García-Álvarez Y, Aragón-Sánchez J, et al. *Preliminary Case Series Results Evaluating Ultrasonic-Assisted Wound Debridement (UAW) for Treatment of Complicated Diabetic Foot Ulcers (DFU)*. Poster presented at ISDF, May 2015, The Hague, Netherlands
- Lázaro-Martínez JL, Álvaro-Afonso F, García-Morales E, et al. *Clinical and Microbiological Outcomes after Sequential Low-Frequency Ultrasound Wound Debridement of Neuroischemic Diabetic Foot Ulcers*. Oral presentation at DFSG, September 2016(b), Stuttgart, Germany
- Yarets Y, Novikova L, Shevchenko N. The Biofilm-forming capacity of staphylococcus aureus from chronic wounds can be useful for determining Wound-Bed Preparation methods. *EWMA Journal* 2013; 13(1)
- Yarets Y, Rubanov L. *Clinical Experiences with Ultrasonic-Assisted Wound Debridement (UAW) Used for Wound Bed Preparation before Skin Grafting*. Paper presented at EWMA, May 2015, London, UK
- Hoffman N, Walters P, Pourhassen S. [Anwendung des Ultraschall-Assistierten Wunddebridements in der täglichen klinischen Praxis der Wundversorgung schwer heilender chronischer Wunden]. Poster presented at EWMA, 2016, Bremen, Germany
- Gray D, Stang D. Ultrasound-assisted wound debridement device. *Wounds UK* 2010; 6(4): 156–62
- European Wound Management Association (EWMA). *Position Document: Wound Bed Preparation in Practice*. London: MEP Ltd, 2004. Available from: <http://woundsinternational.com> (accessed 04.01.16)
- International Best Practice Guidelines. *Wound Management in Diabetic Foot Ulcers*. Wounds International, 2013. Available from: www.woundsinternational.com (accessed 04.01.17)
- Mangram A, Horan T, Pearson M, et al. Guideline for prevention of surgical site infection. Hospital Infection Control Practices Advisory Committee. *Infect Control Hosp Epidemiol* 1999; 20(4): 250–78
- Weber W, Marti W, Zwahlen M, et al. The timing of surgical antimicrobial prophylaxis. *Ann Surg* 2008; 247(6): 918–26
- Guo S, Dipietro L; Factors affecting wound healing. *J Dent Res* 2010; 89(3): 219–29
- Bratzler D, Houck P. Antimicrobial prophylaxis for surgery: an advisory statement from the National Surgical Infection prevention Project. *Clin Infect Dis* 2004; 38: 1706–15
- Sibbald G, Orsted H, Coutts P, et al. Best practice recommendations for preparing the wound bed: update 2006. *Adv Skin Wound Care* 2006; 20(7): 390–405

Summary

Söring UAW is an effective tool for wound debridement that can easily be integrated into treatment pathways for a range of chronic wound aetiologies as an integral part of WBP. As Söring UAW is unique in its approach to debridement, protecting healthy tissue at the wound site while targeting biofilm or damaged tissue, it has potential to play an important role in the management of chronic wounds based on the principles of biofilm-based wound care.



Important information:

Söring UAW made easy

As part of Wounds International's made easy-series, the "Söring UAW made easy" explains the Ultrasonic-Assisted Wound Debridement comprehensively and thus serves as a general procedure overview for users and interested medical professionals. The made easy, written by renowned experts, illustrates UAW's practical aspects as well as the evidence proved effectiveness. "Söring UAW made easy" can be directly obtained from Wounds International.

<http://www.woundsinternational.com/made-easys/view/soring-uaw-made-easy>



The "Quickfinder" document is not intended to remain with the customer or being transferred to a third party. The creation of digital or print copies as well as changes in language or content are prohibited. A quick and simple presentation of the "Söring UAW made easy" content is the only intended use. For questions regarding the "Quickfinder" document, please contact the Söring Product Marketing.